EAJNS East African Journal of Neurological Sciences
Official journal of East African Association of Neurological Surgeons

Case Report EAJNS 5(3): 165 -173

Infected Separated-Type Subdural Hematoma: A Rare Clinical Variant?

Authors: Alliyy Loo[1], Musau Christopher[1], Julius Kiboi[1], Vincent Wekesa[1], Peter Kitunguu[1], Michael Magoha[1], Philip Maseghe Mwachaka[1,2], Mokaya Onsanse[1], Nageyle Faisal[1]

Affiliations:

1. Department of Surgery, University of Nairobi, Nairobi, Kenya.
2. Department of Human Anatomy and Medical Physiology, University of Nairobi, Nairobi, Kenya.

Corresponding author: Alliyy Loo. Email: dr.alliyyloo@yahoo.com
Received: 01-12-2025; Revised: 07-04-2026; Accepted: 26-04-2026
DOI: https://dx.doi.org/10.4314/eajns.v5i3.5

ABSTRACT

Background: Subdural haematoma (SDH) is a prevalent neurosurgical emergency, and its pathophysiology is consistently advancing with the discovery of novel varieties. The separated or multi-layered type, first described by Nakaguchi et al., is a unique pathoanatomic entity with particular imaging and clinical features. **Case summary: T**his report details a rare case of an infected separated-type subdural haematoma in a 38-year-old female with a history of chronic alcohol use, intravenous drug use and head injury. She presented in a comatose condition without fever or focal neurological abnormalities. An axial non-contrast CT scan showed a right fronto-parietal subdural collection with multiple internal septations. We performed burr hole evacuation. Microbiological culture of the drained subdural contents revealed Staphylococcus aureus sensitive to cefotaxime, meropenem, and ceftriaxone. The patient regained full consciousness after the evacuation, and neurological function was intact within 24 hours. Infection of existing subdural hematomas by haematogenous methods is a rare yet complex condition commonly associated with immunosuppression, chronic alcohol use and old age. Common microbes isolated include Staphylococcus aureus, E. coli, H. influenzae, and Salmonella species. **Conclusion:** Infected separated-type SDH constitute a rare yet significant variant of chronic SDH. This condition is often misdiagnosed as a simple chronic subdural hematoma. Rapid diagnosis and appropriate antibiotic management are crucial to patient outcomes.

Keywords: Subdural Hematoma (SDH), Infected Subdural Hematoma, Traumatic Head Injury, Burr-hole

©2026 Author. This article is licensed under Creative Commons Attribution– NonCommercial–NoDerivatives 4.0 International License (CC BY-NC-ND 4.0)

INTRODUCTION

An infected subdural hematoma (ISH) is an uncommon intracranial infection caused by the hematogenous seeding of microorganisms into a pre-existing chronic subdural hematoma (CSDH) (1). Infected subdural hematoma is frequently misdiagnosed as CSDH and subdural empyema; however, there are notable differences in incidence and pathogenesis (1–4). The precise aetiology of CSDH remains unclear, two main theories exist, the first suggests that head trauma leads to rapture of bridging veins causing hematoma development in the subdural space. The second theory points to inflammatory changes and abnormal angiogenesis as key drivers of hematoma formation following trauma. Head injury triggers an inflammatory process leading to

release of mediators such as vascular endothelial growth factor (VEGF), interleukins 6 and 8 (IL6, IL8), bradykinin, tumour necrosis factor α (TNF α), matrix metallo-proteinases (MMPs), and fibroblast growth factor (FGF). This process induces the formation of leaky fragile vessels and impaired clot formation, leading to hematoma growth (5,6). Infection of a CSDH occurs infrequently, with an estimated incidence of 1%. By 2020, approximately 50 cases were documented in the literature and linked to elevated mortality rates (1,2). A systematic review on subdural hematoma mimickers in 2016 reported only 2 cases of ISH (7). On the other hand, a subdural empyema is the accumulation of frank pus in the subdural space, resulting most commonly from paranasal sinus infections, other sources of infection include otitis, head trauma and surgical site infections following neurosurgical procedures (1,2,8).

This case report presents an intraoperatively diagnosed infected subdural hematoma and examines the pathogenesis and diagnosis of ISH.

CASE PRESENTATION

Patient information:

We admitted a 38-year-old homeless female to our facility following an abrupt loss of consciousness; the patient had no preceding history of fever, headache, or infection. In her past medical history, she sustained a traumatic brain injury following a fall while intoxicated 2 months before admission. She is also a tobacco and intravenous drug user. The patient was not on any anticoagulant or antiplatelet medications.

Clinical findings:

The neurological examination indicated a Glasgow Coma Scale (GCS) score of 13/15 (E4, V3, M6) and no lateralising symptoms. Pupils were symmetrical and responsive. Her respiratory exam was normal, with a respiratory rate of 15 breaths per minute and oxygen saturation of 96% on room air. She had warm peripheries and normal capillary refill. She presented with a blood pressure of 123/76 mmHg. Her pulse rate was 71 beats per minute, and there were no murmurs on auscultation.

Investigations:

i) Laboratory Results:

The preoperative laboratory investigations showed low serum sodium levels at 123 mmol/L and elevated white cell, platelet and neutrophil counts (Table 1). Postoperatively, we requested triple serology and C-reactive protein levels.

ii) Imaging:

A non-contrast CT scan of the brain showed a large right fronto-parietal hypodense subdural collection with internal membranes, fluid-fluid levels, and a distinct septated appearance, consistent with a separated-type CSDH (Nakaguchi type III), as shown in Figure 1.

No other imaging, such as X-ray or echocardiography, was performed for this patient.

Diagnosis:

Preoperatively, the patient was diagnosed with a chronic subdural hematoma according to the radiologic appearance. The diagnosis of an infected subdural hematoma was made postoperatively.

Management:

Upon admission, the patient received 3% hypertonic sodium at 2-5 ml/kg 6-8 hourly, targeting a sodium level of 145-155 mmol/L.

We then transferred the patient to the trauma theatre where we performed emergency evacuation of the hematoma through right parietal and frontal burr holes. On opening, we encountered thick, brown foul-smelling fluid under pressure with loculations and noted a distinct membranous separation (Figure 2). We collected the fluid for microscopy, culture and sensitivity. We excised the inner membrane partially for decompression. Using 4 litres of warm saline, we irrigated the cavity until the effluent became clear. We performed the final irrigation with vancomycin-saline fluid flush; this confirmed the communication between the frontal and parietal burr holes. Following the procedure, with the help of the anaesthetist, we performed a Valsalva manoeuvre to facilitate brain re-expansion and reduce the residual cavity.

In the immediate post-operative period, the patient had a GCS score of 9/15; she was intubated and transferred to the neuro-intensive care unit for monitoring. While awaiting culture results, we initiated intravenous (IV) broad-spectrum antibiotics: metronidazole (500 mg TDS), vancomycin (1 g BD) and ceftriaxone (1g BD). We

also provided analgesia, anti-emetics, prokinetics, proton pump inhibitors and anticonvulsants.

The postoperative period was uneventful; she was successfully weaned off the ventilator and extubated on postoperative day 2 with a GCS score of 14/15, with no focal neurologic deficits. On day 4, a non-contrast CT scan of the brain was performed, which showed a well-expanded brain (Figure 3).

Gram stain showed cocci in clusters; culture grew *Staphylococcus aureus,* sensitive to ceftriaxone, ampicillin, cefotaxime, meropenem, ciprofloxacin and trimethoprim-sulfamethoxazole. She received intravenous ceftriaxone (2 g 12 hourly) for 14 days, as it was readily available at our facility. Because of limited resources, i.e., limited bed capacity, we discharged her 7 days later (postoperative day 9) on oral antibiotics.

Outcome and follow-up:

The patient presented to the neurosurgical outpatient clinic 1 week after discharge. She reported no headaches, convulsions or focal neurological deficits, and on examination, she had a GCS score of 15/15 and no lateralising signs. Other systemic examinations were all normal. She was still on analgesics and anticonvulsants (Levetiracetam 500 mg BD orally). The patient was then lost to follow-up.

Ethics:

We obtained written consent from the patient at the facility to share clinical details, laboratory results, radiologic imaging and intraoperative images. We have not included any patient identifiers, including name or hospital identification number, in this manuscript. Due to the retrospective nature of this case and institutional guidelines, no ethical review board approval was required

Table 1: Laboratory investigations, pre-operatively the patient had an elevated white cell count, neutrophilia and thrombocytosis. Upon identification of the ISH, we performed further testing; CRP and Triple serology.

Parameter	Value	Reference range
Pre-operative tests		
Full haemogram		
WBC	11.35 X 10^9/ L	4.00 - 10.00 X 10^9/ L
Neutrophils	10.33 x 10^9/ L	2.00 - 7.00 X 10^9/ L
Lymphocytes	0.79 X 10^9 /L	0.80 – 1.00 X 10^9/ L
Monocytes	0.23 X 10^9 /L	0.12 – 1.20 X 10^9 /L
Eosinophils	0.0 X 10^9 /L	0.02 – 0.50 X 10^9/ L
Haemoglobin	11.9 g/dL	11.00 – 16.00 g/dL
Haematocrit	36.2 %	37.0 – 54.0 %
Platelets	470 X 10^9/ L	100 – 300 X 10^9/ L
Serum Sodium	123 mmol/L	135 – 145 mmol/L
Post-operative tests		
HIV ag/Ab	Non-reactive	
Anti-HCVII	Non-reactive	
HBsAg	Non-reactive	
CRP	54.3 mg/L	(0.2 – 15.0)

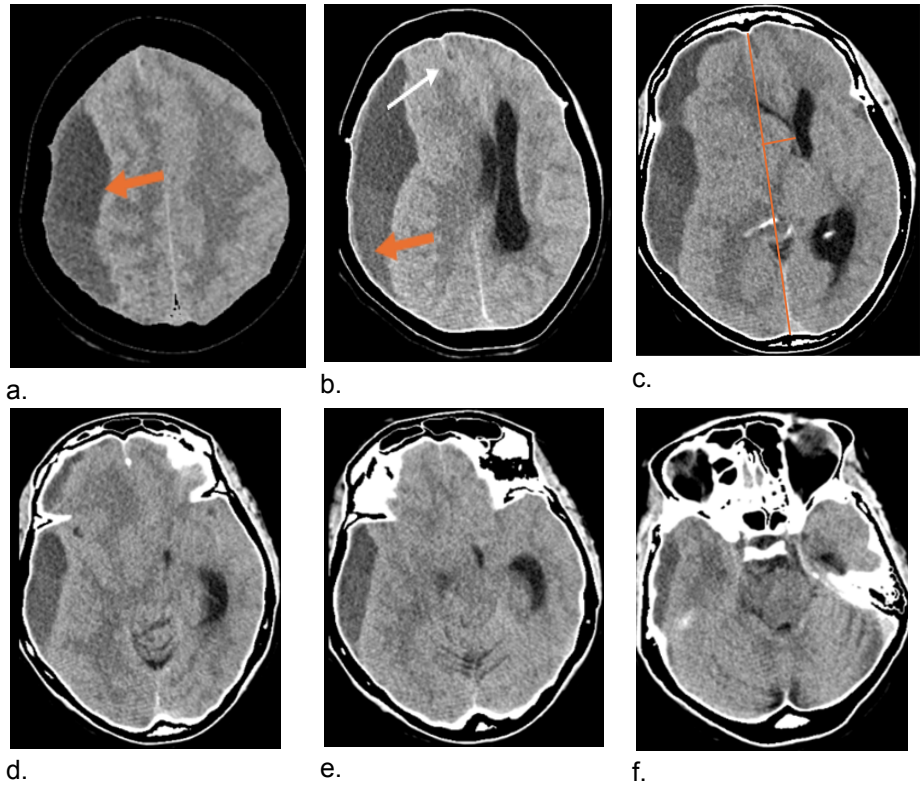

Figure 1: Axial non-contrast CT scan brain window showing a right fronto-parietal subdural collection with mass effect on the right cerebral hemisphere and associated subfalcine herniation (panels a, b, c, d, e, f). A midline shift is present (panel c, 17 mm). The subdural hematoma has a maximum thickness of 34.3 mm at the level of the body of the lateral ventricles (b).

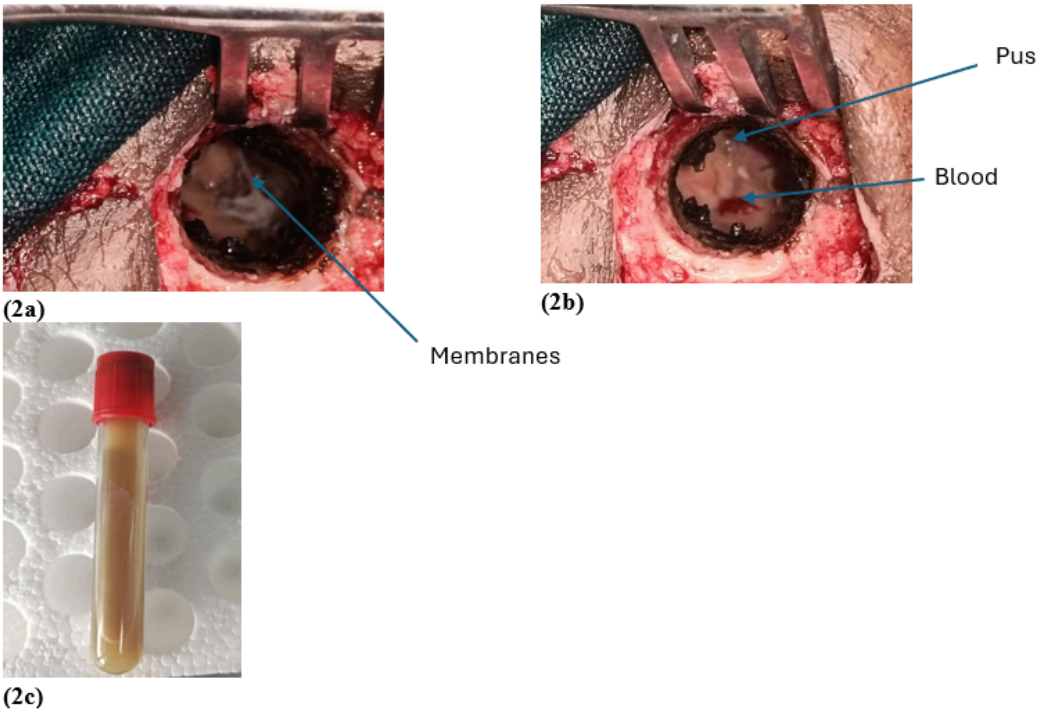

Figure 2: Intraoperative images showing the membranes encountered within the surgical site (a), presence of pus and a minor focal bleed, both of which were evacuated during the procedure (b), and the sample collected from the subdural collection (c).

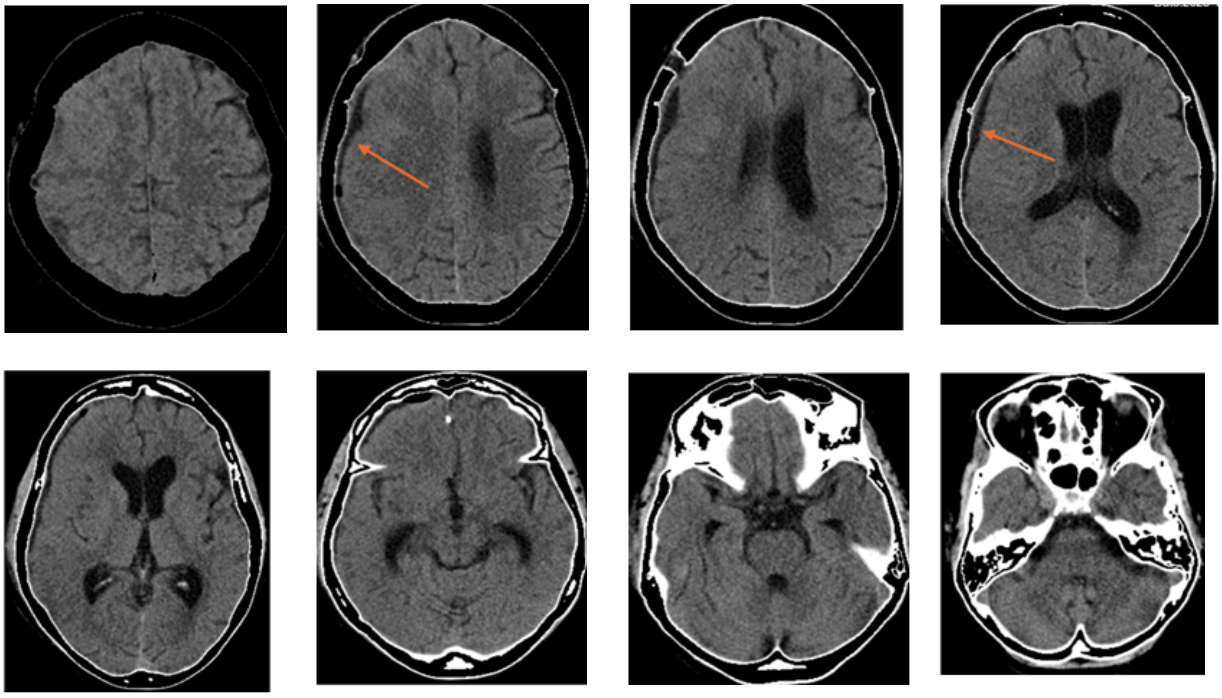

Figure 3: CT scan done on post-operative day 4 showing the brain is well expanded after evacuation of the subdural collection (orange arrow).

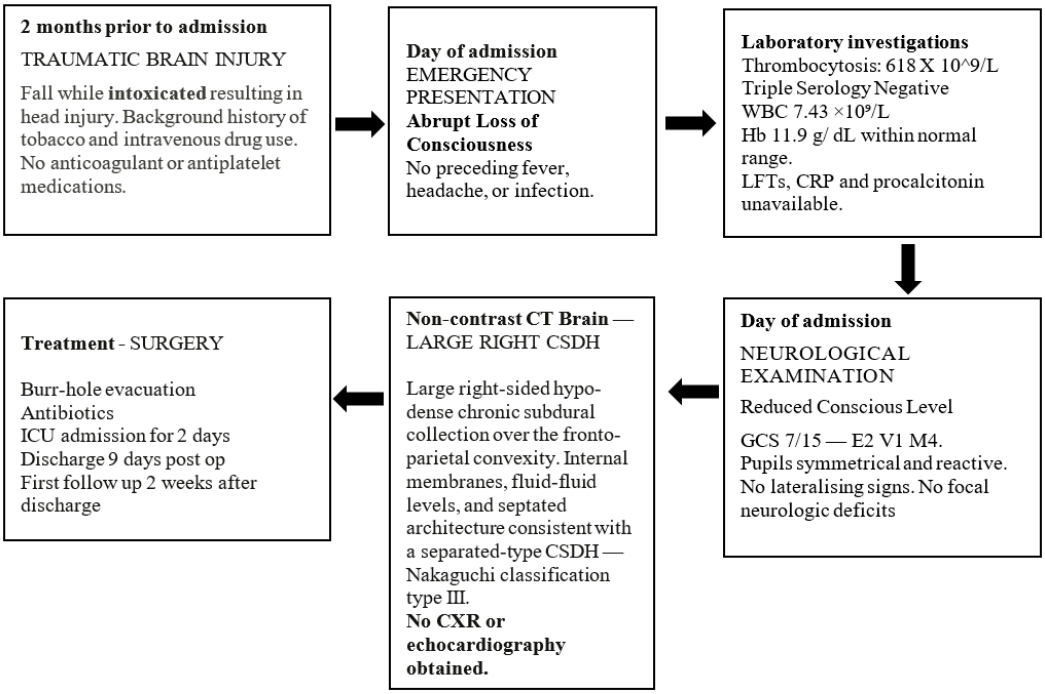

Figure 4: Timeline of management for the patient

DISCUSSION

Chronic subdural hematoma is a prevalent neurosurgical condition particularly affecting the elderly. The annual incidence of this condition has been increasing due to the shift in population dynamics towards the elderly. The estimated global incidence of CSDH ranges from 1.72 to 20.6 cases per 100,000 people (5,6). The peak age of onset has shifted from 50 years in the 1970s to 80 years in more recent years (5). It is more prevalent among men, with a male-to-female ratio ranging from 2:1 to 5:1; the gender disparity decreases with age (5).

The patient presented at the age of 38 years and had no known history of immune dysfunction; however, she is a chronic alcohol and intravenous drug (IVD) user with a preceding history of a fall. Published reports indicate that ISH occurs predominantly in very young individuals (< 1 year old) or in the elderly (> 60 years) with immune dysfunction. A case series by Tamai et al. on 30 published reports regarding ISH indicated that the median age of patients was 71.5 years, with a predominance of male patients (70%, n=21). This series included 2 patients aged 20 and 23 years, 1 patient aged 45 years, and 4 patients in their 5th decade of life (two aged 50 and one each aged 55 and 56 years) (1). This indicates that although the age range for CSDH and ISH may overlap (>60 years); ISH can also manifest in younger individuals.

Chronic alcohol consumption is linked to a heightened risk of development and recurrence of CSDH. One mechanism is the increased risk for traumatic brain injury. On the other hand, the neurotoxic consequences of excessive drinking are linked to accelerated brain atrophy, particularly the shrinkage of the cerebral cortex and white matter; this mechanism is especially significant in elderly alcoholics. The resultant cranio-cerebral disproportion facilitates the separation of the dural layer from the skull, thereby creating a space conducive to hematoma formation. Alcohol is also linked to anomalies in platelet production and function, resulting in protracted bleeding after trauma (5).

Intravenous drug use is associated with an elevated risk for traumatic brain, spinal, or peripheral nerve injuries. It is also linked to an elevated risk of central nervous system infections, particularly in patients with intravenous drug use-related endocarditis (9). According to Hoang et al., IVD users undergoing treatment for infectious endocarditis exhibit neurological complications at a rate of 31.3%, compared to their non-injection drug-using counterparts (23.8%). These complications encompassed intracranial haemorrhage, ischemic stroke due to septic emboli, intracranial mycotic aneurysms, and brain abscesses (10). Conversely, intravenous drug use elevates the chance of HIV infection (9). We did not evaluate our patient for cardiac problems or reasons of immune weakness; nonetheless, injectable drug use may facilitate the admission of pathogenic microorganisms.

In our patient, ISH manifested with altered mental status; however, additional symptoms often found in adults, such as fever and focal neurological deficits, were absent (1,2). The clinical findings in the paediatric populations include fever followed by seizures and focal neurological deficits (2).

The Gram stain revealed cocci in clusters, and the culture identified Staphylococcus aureus, but we could not identify the source of this infection. The microbial agent in ISH is not identified in 50-70% of patients, while E. coli is detected in 30% of samples (1,11). In the paediatric population, H. influenzae, E. coli, Salmonella species, and Staphylococcus aureus are identified (11). The pre-operative hematologic parameters for the patient in this report indicated an ongoing inflammatory response (neutrophilia) typically observed in similar cases (1,3). We did not perform inflammatory marker tests before the surgery.

A 2025 study involving 80 patients managed for CSDH demonstrated that subclinical infection plays a significant role in the development and recurrence of CSDH. The study indicated that, although inflammatory responses such as elevated CRP, leucocytosis, and fever were absent in the patient cohort, microscopic organisms were cultured in 40% of swabs taken during hematoma drainage; the main organism cultured was *C. acnes* (69%), while *S. epidermidis and S. capitis* represented 9% (10). Like our patient, the majority of individuals were treated for chronic subdural hematoma (CSDH), with no notable differences identified in comorbidities, including diabetes and immunosuppression. This research demonstrates that the hematoma serves as an immune-privileged niche for biofilm development (12).

The membrane excised from our patient underwent no histologic assessment. The pathological assessment of membranes in patients with comparable presentations reveals thickening accompanied by significant inflammatory changes in the dura mater (1).

The severe hyponatremia in our patient could have explained the low level of consciousness. This level of sodium is associated with somnolence, confusion, disorientation, decreased consciousness, muscle weakness, falls, seizures, nausea/vomiting and cardiorespiratory distress (13). The non-contrast CT scan of the brain done as per the management protocols for patients presenting with these symptoms at our facility identified the subdural collection.

Computed tomography (CT) is the examination of choice in the diagnosis of CSDH, typically presenting as hypo-intense, isointense or mixed density lesions (6). Initial imaging of our patient showed features suggestive of a separated-type chronic subdural hematoma (Table 2).

The observed separated type in this patient represents a transitional form characterized by internal organization that results in encapsulated compartments. The histological layers represent various ages of blood and fibrovascular septation. This type exhibits the highest recurrence rate, necessitating careful perioperative management and regular postoperative follow-up (14).

Studies suggest that the shape of a hematoma on CT might be indicative of the presence of infection. In the series by Tamai et al., 50% (n=15) of ISH cases exhibited a biconvex shape, whereas only 20.6% (n=21) of CSDH cases displayed this morphology (p=0.0017). Other studies suggest that the presence of high-density regions at the lower end of a hematoma may indicate the presence of ISH; however, this finding is not statistically significant (p=0.13) (1).

In individuals with ISH, the risk of recurrence and death is increased by delayed diagnosis or insufficient drainage (1). The quick recovery of our patient highlights the reversibility of neurologic impairment after the ISH is drained. In line with comparable cases where the care goal was to alleviate a CSDH, prompt surgical evacuation combined with antimicrobial treatment in accordance with microscopy, culture, and sensitivity studies produce a positive outcome (1,3,12).

ISH demonstrates a heightened tendency for recurrence, especially when the implicated pathogen remains unidentified or when suitable antibiotic therapy is not provided. In this instance, craniotomy is advised subsequent to the lesion's recurrence post bur-hole draining. In more severe instances of recurrence, prolonged draining may be required, as seen in the case report by Yamamoto et al., (3). An additional factor contributing to elevated mortality linked to ISH is the spread of infection to the brain parenchyma, resulting in vascular damage. A 2001 investigation suggested that infection was the aetiology of infarction in 70 patients presenting with ischemic stroke of atypical origin (3,15).

This case report has several limitations. First, the diagnostic workup was incomplete, as inflammatory biomarkers such as C-reactive protein (CRP) and procalcitonin were not obtained, limiting assessment of the underlying inflammatory response before surgical intervention. In addition, blood cultures, chest radiography, and echocardiography were not performed, precluding exclusion of infective endocarditis as a potential hematogenous source of infection in this patient with a history of intravenous drug use. Second, histopathological examination of the excised membranes was not undertaken, limiting characterization of the inflammatory and pathological changes associated with infected subdural hematoma. Third, long-term follow-up data were unavailable, preventing assessment of recurrence and long-term neurological outcomes. Finally, as this is a single case report, the findings cannot be generalized or used to establish optimal management strategies or long-term prognostic outcomes.

Table 2: Nakaguchi et al. (2001) classified CSDH based on CT appearance into four main types. (14)

Classification of CSDH	
Homogeneous type	Uniform density throughout the collection.
Laminar type	High-density layer along the inner membrane.
Separated type	Distinct low- and high-density layers separated by a membrane.
Trabecular type	Mixed densities with fibrous strands traversing the hematoma.

CONCLUSION

Our patient had an incidentally diagnosed infected-separated type CSDH, while young and having no identified immune dysfunction. This patient will require meticulous follow up with recurrent imaging. Infected separated-type SDH constitutes a rare yet significant variant of CSDH. This is often misdiagnosed as simple chronic subdural hematoma. Timely neurosurgical intervention and antibiotic administration guided by microbiological analysis improves neurological outcomes.

Funding: This study received no funding.

Conflicts of interest: The authors of this article declare no conflicts of interest.

Consent for publication: Consent was provided.

Author contributions: AL , MO, and JK conceptualized the case report and identified its educational value. All authors were directly involved in the clinical management and surgical care of the patient. AL and NF performed the literature search and gathered the clinical data, including laboratory and radiological images. AL, MM, JK, and NF drafted the initial manuscript narrative, while AL, JK, and NF critically revised the draft for crucial intellectual content. All authors contributed to the editing process, read, and approved the final manuscript for submission.

Acknowledgements: We thank the Kenyatta National Hospital for allowing us to care for this patient and share the case report.

REFERENCES

1. Tamai S, Watanabe T, Ichinose T, Murakami KI, Ueno M, Munemoto S, et al. Morphological characteristics of infected subdural hematoma: Comparison with images of chronic subdural hematoma. Clin Neurol Neurosurg. 2020 Jul;194:105831. doi:10.1016/j.clineuro.2020.105831 PubMed PMID: 32294578.
2. Dabdoub CB, Adorno JO, Urbano J, Silveira EN, Orlandi BMM. Review of the Management of Infected Subdural Hematoma. World Neurosurgery. 2016 Mar 1;87:663.e1-663.e8. doi:10.1016/j.wneu.2015.11.015
3. Yamamoto S, Asahi T, Akioka N, Kashiwazaki D, Kuwayama N, Kuroda S. Chronic Subdural Hematoma Infected by Propionibacterium Acnes: A Case Report. Case Rep Neurol. 2015 Jan 24;7(1):6–14. doi:10.1159/000371841
4. Aoki N, Sakai T, Oikawa A, Takizawa T, Shishido T. Infected Subdural Effusion Associated with Resolving Subdural Hematoma —Case Report—. Neurologia medico-chirurgica. 1997;37(8):637–9. doi:10.2176/nmc.37.637
5. Mehmandoost M, Bahri A, Hasheminejad A, Sharifi H, Oveisi S, Fahim F. Prevalence, etiology, risk factors, management options, and outcomes in chronic subdural hematoma (cSDH): A comprehensive literature review of recent advances. Brain Disorders. 2025 Sep 1;19:100271. doi:10.1016/j.dscb.2025.100271
6. Zhu X, Cheng J, Yang T, Fan K, Ma Y, Yang Y. Updates in Chronic Subdural Hematoma: From Epidemiology, Pathogenesis, and Diagnosis to Treatment. Neurosurgical Subspecialties. 2025 Sep 30;1(3):115–24. doi:10.14218/NSSS.2025.00023
7. Catana D, Koziarz A, Cenic A, Nath S, Singh S, Almenawer SA, et al. Subdural Hematoma Mimickers: A Systematic Review. World Neurosurgery. 2016 Sep 1;93:73–80. doi:10.1016/j.wneu.2016.05.084
8. French H, Schaefer N, Keijzers G, Barison D, Olson S. Intracranial Subdural Empyema: A 10-Year Case Series. Ochsner Journal. 2014 Jun 20;14(2):188–94. PubMed PMID: 24940128.
9. Brust JCM. Neurologic Complications of Illicit Drug Abuse. Continuum. 2014 Jun;20(3):642–56. doi:10.1212/01.CON.0000450971.99322.cd
10. Hoang AN, Shah V, Granger J, III DD, Youssef PP, Powers CJ, et al. Intravenous Drug Use-Associated Endocarditis Leads to Increased Intracranial Hemorrhage and Neurological Comorbidities. Stroke: Vascular and Interventional Neurology. 2023 Sep;3(5):e000806. doi:10.1161/SVIN.122.000806
11. Iimura Y, Tsutsumi S, Mitome Y, Nonaka Y, Abe Y, Yasumoto Y, et al. Infantile Chronic Subdural Hematoma Infected by Escherichia Coli. Neurologia medico-chirurgica. 2010;50(6):482–4. doi:10.2176/nmc.50.482
12. Dubinski D, Won SY, Rafaelian A, Duran SH, Rohwer M, Freitag T, et al. Subclinical low-grade infection in untreated primary chronic subdural hematoma [Internet]. 2025 Nov 7. doi:10.3171/2025.7.JNS251083
13. Rout P, Badireddy M. Hyponatremia. In: StatPearls [Internet] [Internet]. StatPearls Publishing; 2025 [cited 2026 Mar 31]. Available from: https://www.ncbi.nlm.nih.gov/books/NBK470386/ PubMed PMID: 29262111.
14. Nakaguchi H, Tanishima T, Yoshimasu N. Factors in the natural history of chronic subdural hematomas that influence their postoperative recurrence. J Neurosurg. 2001 Aug;95(2):256–62. doi:10.3171/jns.2001.95.2.0256 PubMed PMID: 11780895.
15. Arboix A, Bechich S, Oliveres M, García-Eroles L, Massons J, Targa C. Ischemic stroke of unusual cause: clinical features, etiology and outcome. Eur J Neurol. 2001 Mar;8(2):133–9. doi:10.1046/j.1468-1331.2001.00180.x PubMed PMID: 11430270.